

Mass Circumcision with a Novel Plastic Clamp Technique

Ferda M. Senel, Mustafa Demirelli, and Hikmet Pekcan

OBJECTIVE METHODS

To evaluate the safety and efficacy of mass circumcision performed using a plastic clamp.

A total of 2013 males, including infants, children, adolescents, and adults were circumcised during a 7-day period by using a plastic clamp technique. Complications were analyzed retrospectively in regard to 4 different age groups. Postcircumcision sexual function and satisfaction rates of the adult males were also surveyed.

RESULTS

The mean duration of circumcision was 3.6 ± 1.2 minutes. Twenty-six males who were lost to follow-up were excluded from the study. The total complication rate was found to be 2.47% among the remaining 1987 males, with a mean age of 7.8 ± 2.5 years. The highest complication rate (2.93%) was encountered among the children <2 years age, which was because of the high rate of buried penis (0.98%) and excessive foreskin (0.98%) observed in this group. The complication rates of older children, adolescents, and adults were slightly lower than the children <2 years age, at 2.39%, 2.51%, and 2.40%, respectively. Excessive foreskin (0.7%) was the most common complication observed after mass circumcision. Bleeding (0.6%), infection (0.55%), wound dehiscence (0.25%), buried penis (0.25%), and urine retention (0.1%) were other encountered complications. The erectile function and sexual libido in adolescents and adults was not affected by circumcision and a 96% satisfaction rate was obtained.

CONCLUSIONS

Mass circumcision performed by a plastic clamp technique was found to be a safe and time-saving method of circumcising a large number of males at any age. UROLOGY 78: 174–179, 2011.

© 2011 Elsevier Inc.

Circumcision is the most common surgical procedure practiced mainly for religious reasons and is also a social ceremony in our country. For the child to be aware of this ceremony, families usually prefer the circumcision age to be >5 years of age, the mean age being 7. There are nearly 1.2 million new births per year reported in Turkey, nearly half of which are male.¹ The prevalence of circumcision is around 99%; accordingly, every year nearly 600,000 male children are circumcised. Circumcision is associated with various complications, mostly minor and treatable, such as bleeding, wound infection, or phimosis. However, severe complications, such as urethral fistula or amputation of the glans have also been reported in some studies.^{2,3} The complication rate is found to be higher among the circumcisions performed by traditional circumcisers.^{4,5} The easily applicable plastic clamp technique has emerged as a relatively safe circumcision procedure in reducing the complication rates.

Mass circumcision is a traditional cost-effective way of circumcising a large number of children in developing countries, such as Turkey. Unfortunately, mass circumcision results in a higher rate of complications.⁶ There is only one previous study from our country reporting the results of mass circumcision that included 700 children circumcised within 5 days in a hospital.⁶ We report for the first time the analysis of the results of mass circumcision performed outside of the hospital by a medical team using a plastic clamp technique.

MATERIALS AND METHOD

Subjects

A total of 2013 males, including infants, children, adolescents, and adults (mean age 7.8 ± 2.5 years) were circumcised during a 7-day period in June 2009, sponsored by the Turkish Public Health Association. The study patients originated from 6 different locations in the central Anatolia region of Turkey (districts of Kırıkkale and Kırşehir). All males whose families could not afford the expenses of the private circumcision were accepted for mass circumcision. Males with a history of bleeding disorder or severe allergy, particularly to analgesic or antibiotics, were referred to local hospitals. Males with genital anomalies, such as hypospadias or micropenis, were not circumcised. Circumcisions were performed by a team consisting of a urologist, a general surgeon, a pediatrician, 3 practitioners, and 6 nurses. The team circumcised nearly 300 boys per day in a

From the Department of Pediatric Urology, Dr. Sami Ulus Women's and Children's Hospital, Ankara, Turkey; and Department of Public Health, Hacettepe University, Ankara, Turkey

Reprint requests: Ferda M. Senel, M.D., Department of Pediatric Urology, Dr. Sami Ulus, Women's and Children's Hospital, Babur Caddesi, Telsizler, Ankara, Turkey. E-mail: mfsenel@yahoo.com.tr

Submitted: November 16, 2010, accepted (with revision): December 14, 2010.



Figure 1. Components of the Alisklamp.

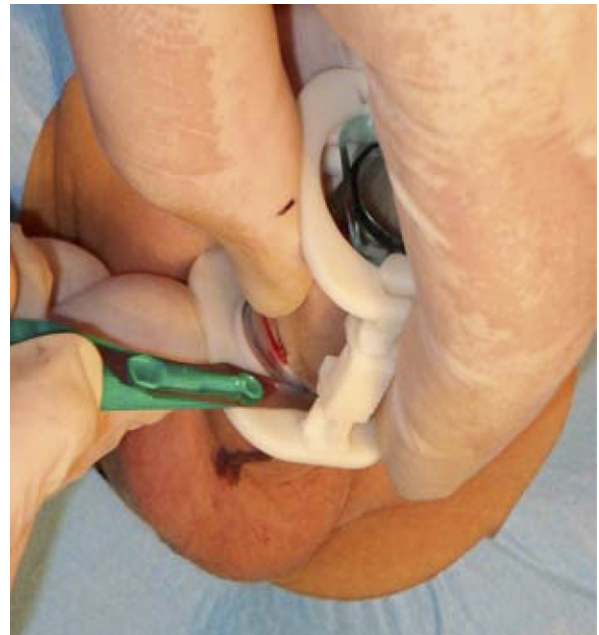

Figure 2. The foreskin squeezed between the inner tube and the outer ring is excised.

primary health care center that did not have a standard operating room.

Technique

All males were circumcised by using the Alisklamp (Telif Hakları Abigroup Ltd.) technique under local anesthesia. One sterile disposable circumcision set, including a plastic sizer, hemostat, drape, and blade, was used for each male. Disposable plastic clamps are available in a separate sterile package. Local infiltrative anesthesia was applied using 0.8-4 mL of 1% lidocaine after sterile cleansing of the penis. The Alisklamp consists of 2 plastic components, an inner tube and an outer ring (Fig. 1), in various sizes starting from 12 mm in diameter. Circumference of the glans was measured by using the sizer before deciding on the appropriate clamp size. Clamp sizes 12, 14, 16, 18, 20, 26, 30, and 34 mm were used depending on the circumference of the glans penis. Initially, the foreskin was retracted completely to expose the glans. Then an inner tube was placed over the glans penis. After placement of the inner tube, the retracted foreskin was pulled over this tube and an outer ring was placed over the foreskin. The foreskin that was squeezed between the inner tube and the outer ring was consequently excised with a number 11 surgical blade. The apparatus was left for 2-4 days to hold the cut wound edges (Fig. 2). Medications to prevent penile erections were not prescribed to adults, because separation of the plastic clamp caused by erection was not expected.

There was no need for special wound care or dressing after circumcision. The plastic apparatus was safely removed (within a mean of 15 ± 7 seconds) without any difficulty 2-4 days after circumcision, depending on age. The plastic apparatus was removed earlier in the infants (2-3 days) because of faster wound healing. The removal time was 4 days for older children and adults. There was no need for local anesthesia, and any complication, such as bleeding or penile injury, was not encountered during the removal procedure. All families were called for a follow-up visit within 1 week and 6 weeks after the

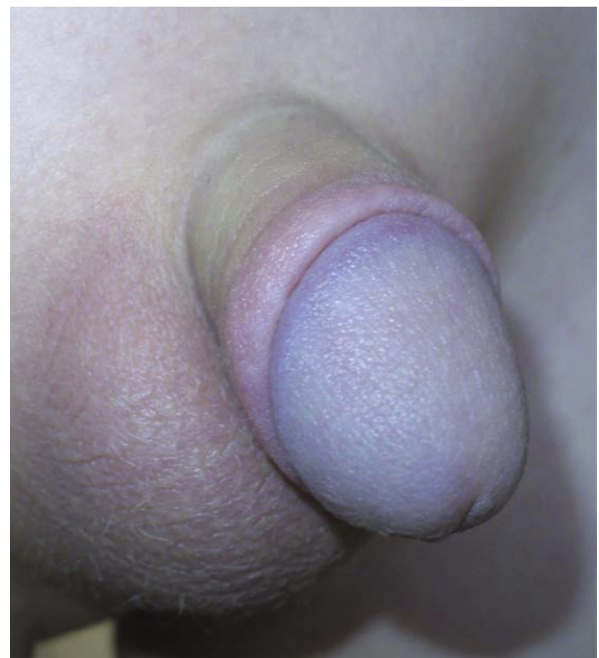


Figure 3. Appearance of a penis 21 days after circumcision using the Alisklamp.

removal of the plastic clamp. Wound healing was defined as disappearance of the crusts and total appearance of the incision line (Fig. 3). The mean cost of circumcision with the plastic clamp technique was US \$20, which was an acceptable cost for mass circumcision in our country.

Analysis

The rate of complications was analyzed retrospectively in regard to age groups, such as babies with diaper, children, adolescents, and adults. Differences between the groups were analyzed by

analysis of variance. PASW Statistics 18 (SPSS, Inc., Chicago, IL) was used for the data analysis and the significance level was accepted as 0.05. In addition, adult males were further questioned about postcircumcision sexual function and satisfaction from the procedure. Occurrences of daytime and nighttime erections, as well as sexual desire, were accepted as criteria of sexual function. The advisability of the circumcision procedure was the criterion for satisfaction rate.

RESULTS

A mass circumcision was performed in June 2009 on 2013 males, with ages ranging from 3 months to 28 years. Twenty-six males who were lost to follow-up or were not found at their given address were excluded from the study. The remaining 1987 males were included in the evaluations. The mean follow-up period was 43 ± 7 days. Of the 1987 males, 205 (10.32%) were under age 2 years, 1338 (67.34%) were between 3 and 12 years, 319 (16.05%) were between 13 and 17 years, and 125 (6.29%) were 18 years of age or older (Table 1).

The mean duration of circumcision and removal of the clamp was 3.6 ± 1.2 minutes and 15 ± 9 seconds, respectively. Analgesic medications were used for a mean of 22 ± 6.2 hours after circumcision. In 158 males (8%), the need for analgesics was <6 hours. Complications such as bleeding, excessive foreskin, buried penis, wound infection, urinary retention, and wound dehiscence were observed in 49 males. The total complication rate was 2.47% (Table 1). We did not encounter serious complications such as amputation of glans penis, necrosis of penis, sepsis, or penile fistula, as well as any penile injury related to delayed separation of the ring as we removed the clamp 2–4 days after circumcision.

We encountered 12 cases of bleeding (0.6%), 3 of which were caused by penile trauma and 10 within 24 hours after the removal of the clamp. Of those 12 cases, two had bleeding caused by trauma while the plastic clamp was on. The plastic clamp was removed immediately to stop the bleeding in these cases. Of the 12 bleeding cases, 8 ceased to bleed within 5–15 minutes of compression at the wound edge, and 4 required suturing to maintain homeostasis. Sterile dressing was applied in all 12 cases and was removed within 24 hours. Of these 4 patients who required suturing, one was under <1 year and the other 3 were between 4 and 8 years. Bleeding that required suturing was not observed among adolescents and adults. Eleven patients (0.55%) had wound infection; none of these patients had systemic symptoms, such as fever, and all were managed by application of a local antibiotic cream.

Foreskin covering nearly half of the glans despite adequate compression of prepubic adipose tissue was accepted as excessive foreskin; 14 patients (0.7%) had excessive foreskin. Surgical revision was not performed in any of these cases because the excessive foreskin was thought to disappear within time parallel to the increase in penile length. Buried penis was analyzed as a separate entity, and was accepted as healing of wound edges above

Table 1. Complications of Mass Circumcision

Age	N	%	Bleeding	%	Excessive Foreskin	%	Buried Penis	%	Infection	%	Urinary Retention	%	Wound Dehiscence	%	Total Complications	%
Babies with 0-2 y	205	10.32	1	0.49	2	0.98	2	0.98	1	0.49	0	0	0	0	6	2.93
Children 3-12 y	1338	67.34	9	0.67	10	0.75	3	0.22	7	0.52	2	0.15	1	0.07	32	2.39
Adolescent 13-17 y	319	16.05	2	0.63	2	0.63	0	0	2	0.63	0	0	2	0.63	8	2.51
Adult ≥ 18 y	125	6.29	0	0	0	0	0	0	1	0.80	0	0	2	1.60	3	2.40
Total	1987	100	12	0.60	14	0.70	5	0.25	11	0.55	2	0.1	5	0.25	49	2.47

the glans penis and causing a constrictive ring at this level, resulting in phimosis in 5 patients (0.25%). The highest rates of buried penis and excessive foreskin were encountered among the children <2 years (0.98%; $P < .01$), which also reflected the total complication rate of this group (2.93%) (Table 1). Two of the children with buried penis were <2 years. The other 2 were 3 and 4 years. All children with buried penis were over the 95th percentile in body weight. Postcircumcision phimosis was managed by dilating the constrictive ring under local anesthesia and applying a penile massage for 2-3 weeks. Penile massage was performed by the family, by retracting the penile skin by applying compression on the prepubic adipose tissue. Postcircumcision excessive foreskin or buried penis was not observed among adolescents and adults.

Urinary retention occurred in 2 children (0.1%), and plastic clamp was removed on the first postcircumcision day. After removal of the clamp, examination did not reveal a meatal injury. Urinary retention was attributed to pain and fear in the children, which prevented them from urination. A compressive dressing covering the wound was applied and no hemorrhage was observed in these children.

The mean duration of wound healing was 12.6 ± 2.4 days for children <2 years and 24.3 ± 4.7 days for older ages. Wound dehiscence, defined as separation of wound edges more than 2 mm, was observed in 4 patients. Wound dehiscence was symmetric and caused by trauma.

Adults were questioned for the existence of day and night erections, quality of erection, and status of libido at their first follow-up visit. The follow-up period was short (mean, 10 days) and none of the patients initiated intercourse within this period. Erectile function, particularly nocturnal erection, was intact in all adults and none complained of a decrease in libido. The majority of patients (96%) recommended the plastic clamp method to others.

COMMENT

The circumcision rate has a wide variation in different countries, eg, it is 99% in Muslim countries as opposed to 5% in the United Kingdom.⁷ In Turkey, circumcision is routinely performed in all Muslim males for religious reasons. Some families do not have the opportunity to have their children circumcised because of low socioeconomic status as well as a lack of an adequate number of health professionals in rural areas. Mass circumcision sponsored by municipalities or charities seems to be a practical approach to circumcise a large amount of the male population. However, the complication rate of mass circumcision was found to be significantly high and severe unwanted events were reported.^{4,6} The highest complication rates were observed after the circumcisions performed by traditional circumcisers who are not medically trained health providers. Complication rates of 63-85% and severe events such as amputation of penis have been

reported in previous studies.^{4,5,7} These rates are significantly higher when compared with complications of circumcisions performed by medical professionals.^{9,10} Most of these studies include patients circumcised with the conventional dissection and suturing technique. As an alternative, minimally invasive circumcision techniques using plastic devices are becoming popular because of their easy application and lower complication rates. Recently, we have reported the results of circumcisions performed either by conventional or plastic clamp techniques in 13,200 males in Turkey.¹¹ The total rate of unwanted events was found to be significantly lower among the patients circumcised using the plastic clamp technique compared with those circumcised using the conventional technique (2% vs 10.4%, respectively; $P < .001$). A higher incidence of adverse events among the males circumcised by conventional technique was also reported by other groups in different parts of the world.¹²⁻¹⁴ In the current study, we evaluated the safety of the plastic clamp technique in mass circumcision.

Bleeding is accepted as the most life-threatening and common complication of conventional circumcision, reaching a rate of 36%.¹⁵⁻¹⁸ In contrast, it was observed to be an uncommon adverse event in mass circumcision performed using the plastic clamp technique in our study (0.6%). Most of the bleeding cases were minor, and only one-third (4/12) required suturing to maintain homeostasis. The bleeding rate observed in our study was also considerably lower than the bleeding rate of 3.6% reported in a previous study on mass circumcision, where 700 children were circumcised in a single center during a 5-day period.⁶ The variation in bleeding rates between the 2 studies is attributed to the difference in the circumcision techniques. A conventional technique using sutures was performed in the circumcisions of the 700 children in that study, whereas the plastic clamp technique was performed for all males in our study. In our previous study where the 2 techniques were compared, a high bleeding rate (5%) was observed after conventional circumcision, whereas the bleeding rate was only 0.4% after performing the plastic clamp technique.¹¹ The bleeding rate after mass circumcision was slightly higher than that after single circumcision. This was attributed to a higher incidence of trauma because of inadequate care provided by the families in rural areas. Nevertheless, the total bleeding rate seen after mass circumcision is still lower than the average rate of 1% reported in the literature.¹⁶

Excessive residual foreskin (0.7%) was the most common adverse event we observed after mass circumcision, despite the data indicating that the most common postoperative complications are local infection and bleeding.¹⁹ Excessive foreskin was analyzed separately vs buried penis because we were not able to find a correlation between the amount of redundant foreskin and phimosis. The highest rates of buried penis (0.98%) and excessive foreskin (0.98%) were encountered among the infants

($P < .01$). Because of this, the highest rate of complication was observed in this group (2.93%) despite the lower incidence of bleeding and infection compared with other age groups. The rate of inadequate circumcision and secondary phimosis was reported to be between 2.10% and 11.8% after a mass circumcision.^{4,6} In another study that included 3205 children who underwent single circumcisions, the rate of excessive residual foreskin was reported to be 3.6%.²⁰ The total rate of excessive foreskin and buried penis was less than 1% in our study, which is acceptable even for single circumcisions. These complications were observed among overweight children, and no surgical revision was needed in any of them. A long-term follow-up study that included infants with buried penis revealed that this appearance was not permanent and usually resolved parallel to growth of the infant.²¹

Although infection is a common complication after mass circumcisions, it was rarely encountered (0.55%) in our study.^{4,6,8} An infection rate of 14.3% was reported after a mass circumcision performed by traditional circumcisers.⁴ Even in a mass circumcision performed by medical providers in hospital, the infection rate was reported to be 2.1%.⁶ It is apparent that the rate of 0.55% observed in this study after mass circumcisions performed by plastic clamp techniques is profoundly lower than those reported in other studies. In mass circumcisions, common debates arise regarding the sterility of the surgical instruments. Hundreds or even thousands of children are operated within a short period during mass circumcisions. Proper sterilization of an adequate number of surgical instruments may not be possible during mass circumcisions. This may be one of the reasons for the high infection rate seen after mass circumcisions. In our circumcisions, a separate disposable sterile set was used for every patient, which was an important factor in reducing the infection rate. The used technique also seems to be an important determinative factor affecting the infection rate. In our previous study comparing the conventional and plastic clamp techniques, we observed a 7-fold increase in the infection rate among the circumcisions performed using the conventional technique.¹¹ The low infection rate after plastic clamp circumcision is also attributed to the fact that the wound was not exposed to an outside environment during the first 2-4 days after the circumcision, which avoided contamination of the wound.

The plastic clamp technique did not cause any serious injury to the penis, such as necrosis, fistula, or amputation. Injury related to delayed separation of the ring is an important complication of some minimally invasive plastic apparatuses, which limits their use beyond the age of 12 months.²² This complication occurs because of a delay in the duration of spontaneous fall-off of the apparatus. The problem of delayed separation of the ring was not encountered in our technique because the apparatus was removed 2-4 days after circumcision. Thus, we were able

to use the technique safely in all age groups, which is not the possible for some of the similar devices.

Data regarding the adolescent and adult age groups are usually reported from Africa, where circumcision is performed mainly to reduce the incidence of HIV contraction. A study held in Kenya reported a frequency of adverse events as high as 35.2% among males circumcised traditionally. The rate of adverse events was reduced to 17.7% when the circumcisions were performed by medical health providers.²³ Despite reports on the high incidence of adverse events after adolescent and adult circumcisions, in this study, a rather low rate of adverse events was observed. In addition, sexual function of the adult males was not adversely affected by circumcision and a high satisfaction rate was obtained. Our results showed that circumcision with the plastic clamp method is a remarkably safe procedure for the adolescent and adult age groups.

CONCLUSION

The retrospective analysis and the relatively short follow-up period are the major limitations of this study, yet it is the first study from our country to evaluate the results of mass circumcision performed outside the hospital. According to our results, use of the plastic clamp during mass circumcision is associated with a low total complication rate (2.47%), which is similar to the results of single circumcisions (2%).¹¹ It can be concluded that mass circumcision performed by surgeons or medical health providers using the plastic clamp technique is a safe and also a time-efficient way of circumcising a high number of males at any age.

References

1. Fişek NH. A new institute at the Hacettepe Science Center: Hacettepe Institute of Population Studies. *Turk J Pediatr*. 1966;8: 237-239.
2. Ceylan K, Burhan K, Yilmaz Y, et al. Severe complications of circumcision: an analysis of 48 cases. *J Pediatr Urol*. 2007;3:32-35.
3. Gluckman GR, Stoller ML, Jacobs MM, et al. Newborn penile glans amputation during circumcision and successful reattachment. *J Urol*. 1995;153:778-779.
4. Atikeler MK, Geçit I, Yüzgeç V, et al. Complications of circumcision performed within and outside the hospital. *Int Urol Nephrol*. 2005;37:97-99.
5. Lee RB. Filipino experience of ritual male circumcision: knowledge and insights for anti-circumcision advocacy. *Cult Health Sex*. 2006; 8:225-234.
6. Ozdemir E. Significantly increased complication risks with mass circumcisions. *Br J Urol*. 1997;80:136-139.
7. Schoen EJ. The status of circumcision of newborns. *N Engl J Med*. 1990;322:1308-1312.
8. Ahmed A, Mbibi NH, Dawam D, et al. Complications of traditional male circumcision. *Ann Trop Paediatr*. 1999;19:113-117.
9. Weiss HA, Larke N, Halperin D, et al. Complications of circumcision in male neonates, infants and children: a systematic review. *BMC Urol*. 2010;10:1-13.
10. Brisson PA, Patel HI, Feins NR. Revision of circumcision in children: report of 56 cases. *J Pediatr Surg*. 2002;37:1343-1346.
11. Senel FM, Demirelli M, Oztek S. Minimally invasive circumcision with a novel plastic clamp technique: a review of 7,500 cases. *Pediatr Surg Int*. 2010;26:739-745.

12. Mousavi SA, Salehifar E. Circumcision complications associated with the Plastibell device and conventional dissection surgery: a trial of 586 infants of ages up to 12 months. *Adv Urol*. 2008;606123, E-pub.
13. Bastos-Netto JM, de Araújo JG Jr., de Almeida-Noronha MF, et al. Prospective randomized trial comparing dissection with Plastibell® circumcision. *J Pediatr Urol*. 2010;6:572-577.
14. Aldemir M, Cakan M, Burgu B. Circumcision with a new disposable clamp: is it really easier and more reliable? *Int Urol Nephrol*. 2008;40:377-381.
15. Williams N, Kapila L. Complications of circumcision. *Br J Surg*. 1993;80:1231-1236.
16. Warner E, Strashin E. Benefits and risks of circumcision. *CMAJ*. 1981;125:967-976.
17. Griffiths DM, Atwell JD, Freeman NV. A prospective survey of the indications and morbidity of circumcision in children. *Eur Urol*. 1985;11:184-718.
18. Gee WF, Ansell JS. Neonatal circumcision: a ten-year overview: with comparison of the Gomco clamp and the Plastibell device. *Pediatrics*. 1976;58:824-827.
19. American Academy of Pediatrics. Report of the Task Force on Circumcision. *Pediatrics*. 1989;84:388-391.
20. Yegane RA, Kheirollahi AR, Salehi NA, et al. Late complications of circumcision in Iran. *Pediatr Surg Int*. 2006;22:442-445.
21. Eroglu E, Bastian OW, Ozkan HC, et al. Buried penis after newborn circumcision. *J Urol*. 2009;181:1841-1843.
22. Samad A, Khanzadai TW, Basant-Kumar B. Plastibell circumcision: A minor surgical procedure of major importance. *J Pediatr Urol*. 2010;6:28-31.
23. Bailey RC, Egesah O, Rosenberg S. Male circumcision for HIV prevention: a prospective study of complications in clinical and traditional settings in Bungoma, Kenya. *Bull World Health Organization*. 2008;86:669-677.